

Bilateral Naviculocuneiform Coalitions: Using Multi-Planar Reconstruction Computed Tomography

TOSHIHIRO AKISUE, MD; TETSUJI YAMAMOTO, MD; TAKASHI MARUI, MD; TOSHIKI HITORA, MD; KEIKO NAGIRA, MD; TETSUYA NAKATANI, MD; SHINICHI YOSHIYA, MD; MASAHIRO KUROSAKA, MD

Congenital tarsal coalition is a known disorder in pediatric and adolescent patients who present with persistent foot pain. Talocalcaneal and calcaneonavicular coalitions are most frequently encountered, but naviculocuneiform coalition is uncommon.¹⁻³ Tarsal coalition often is overlooked in plain radiographs of the feet.

This article reports a case of bilateral naviculocuneiform coalitions diagnosed using multi-planar reconstruction computed tomography (CT).

CASE REPORT

A 16-year-old girl presented with left foot pain of 2 months' duration. She reported pain when walking, but experienced no pain at rest.

Physical examination revealed no swelling or local heat in the left foot or ankle. Range of motion of the left ankle, forefoot, and hindfoot was normal. Local tenderness was noted in the inferomedial aspect of the first naviculocuneiform joint. Mild bilateral flat feet were noted.

Initial radiographs of both feet showed mild sclerotic changes in both naviculars near the first naviculocuneiform joints. Painful flat foot was diagnosed and conservatively treated with an arch support for the left foot. Three months later, the patient developed right foot pain, after which an arch support was also applied. Right foot pain was alleviated, but left foot pain persisted.

Nine months after initial presentation, CT

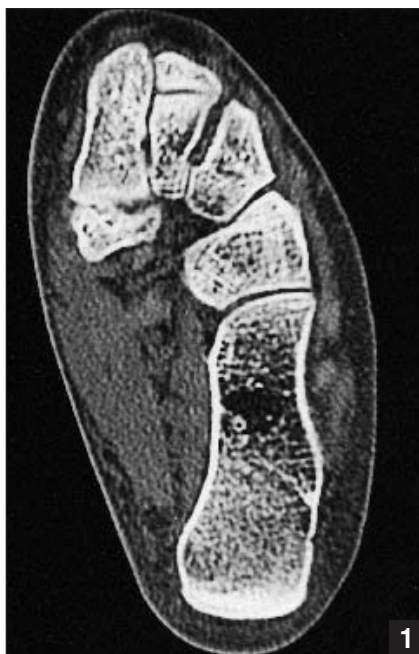

Figure 1: Conventional axial CT of the left foot, showing irregularity, sclerosis, and cyst formation in the first naviculocuneiform joint.

examination was performed using a multi-detector CT scanner (Siemens Plus 4 Volume Zoom; Siemens Medical Systems, Iselin, NJ), with a multi-planar reconstruction technique. Parameters included 1-mm detector collimation with 1-mm slice thickness. Multi-planar reconstruction images were created on a commercially available workstation. After axial images were acquired, the images were reconstructed in the sagittal plane and the perpendicular plane to the first naviculocuneiform joint.

Conventional axial CT revealed irregularity and sclerosis with cyst formation in the first naviculocuneiform joint, consistent with nonosseous naviculocuneiform coalition (Figure 1). Sagittal reconstruction revealed a localized coalition in the inferior part of the joint (Figure 2A). An image reconstructed perpendicularly to the first naviculocuneiform joint revealed a coalition in the medial portion of the joint (Figure 2B). ^{99m}Tc scintigraphy showed increased isotope uptake in both first naviculocuneiform joints.

The patient underwent excision of the fibrous coalition of the left foot. Three weeks postoperatively, the patient reported right foot pain. Sagittal and axial reconstruction images revealed the coalition in the inferomedial portion of the first naviculocuneiform joint (Figure 3).

The patient was treated with local steroid injections and an arch support for the right foot. The patient was asymptomatic 8 months postoperatively.

DISCUSSION

Talocalcaneal and calcaneonavicular coalitions account for >90% of all tarsal

From the Department of Orthopedic Surgery, Kobe University Graduate School of Medicine, Kobe, Japan.

Reprint requests: Tetsuji Yamamoto, MD, Dept of Orthopedic Surgery, Kobe University Graduate School of Medicine, 7-5-1 Kusunoki-cho, Chuo-ku, Kobe 650-0017, Japan.

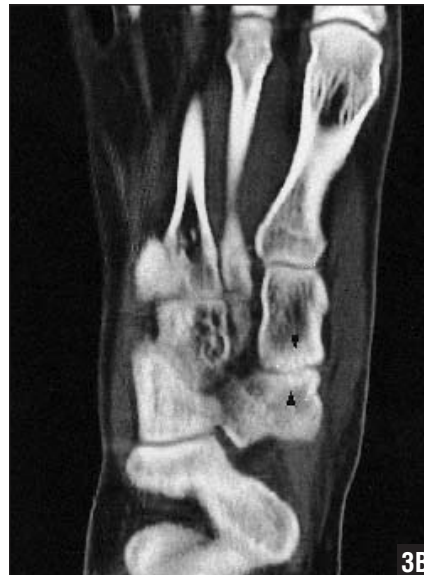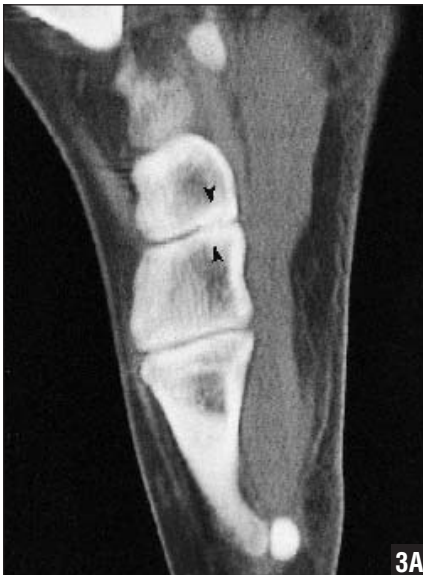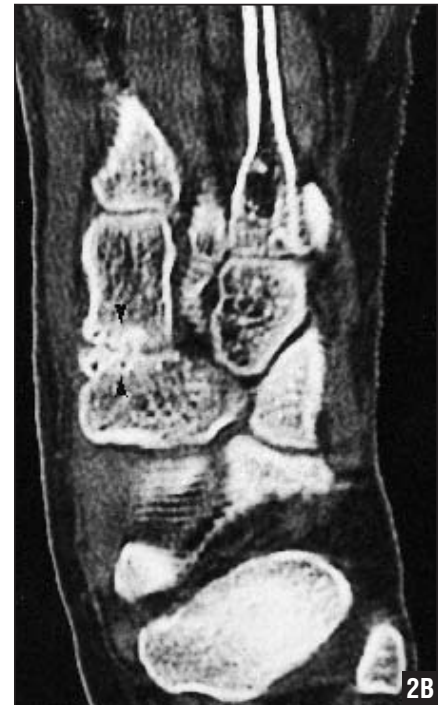
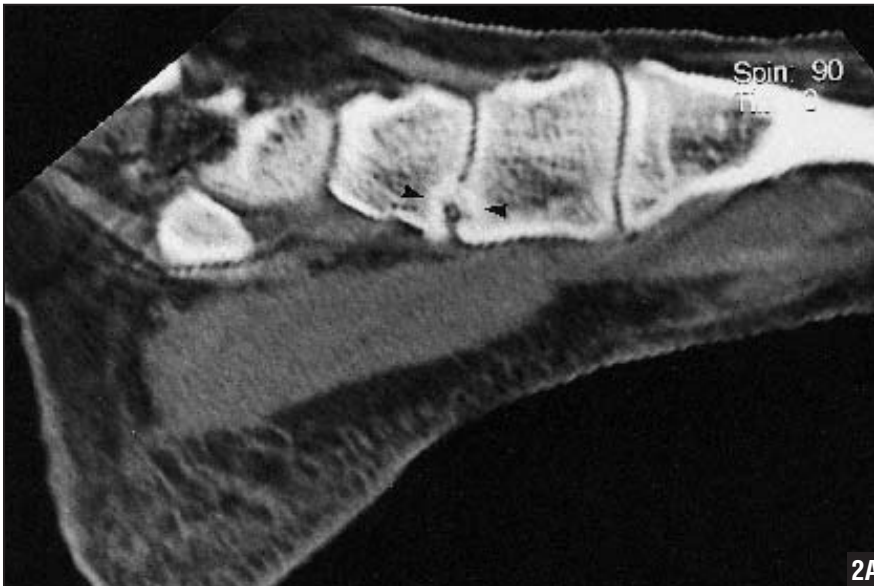


Figure 3: Sagittal reconstruction CT of the right foot showing a coalition in the inferior part of the joint (arrows) (A). Axial reconstruction CT of the right foot showing mild articular narrowing and sclerosis in the first naviculocuneiform joint (arrows) (B).

coalitions.¹⁻³ According to Stormont and Peterson,⁴ the relative incidence of talocalcaneal coalition is 48% and calcaneonavicular coalition 43%. Approximately 50%-60% of these coalitions occur bilaterally.^{1,3}

Naviculocuneiform coalition is a rare type of tarsal coalition. The majority of

articles describing naviculocuneiform coalitions are isolated case reports.⁵⁻⁸ Kumai et al⁹ reported the only large series, describing 60 feet in 40 Japanese patients with naviculocuneiform coalitions. Their series consisted of 59% talocalcaneal coalition, 30% first naviculocuneiform, and approximately 11% calca-

neonavicular coalition.⁹ With the advent of CT and magnetic resonance imaging (MRI), tarsal coalitions are being diagnosed more frequently.^{2,3,10-13} Sarno et al¹⁴ recommended two views for tarsal coalitions on CT—a coronal (short axis of foot) and an axial (long axis of foot) view. Wechsler et al¹² described the use of direct, non-reformatted CT in the sagittal plane.


In the present study, multi-planar reconstruction CT was used following coronal or axial images. This technique enabled the authors to identify the location and extent of the coalitions, reduce the scanning time, and reduce the risk of exposure to irradiation. The multi-planar CT images were useful in surgical planning. Kumai et al⁹ also described the imaging modality as the best method to differentiate between coalition and osteoarthritis.

A multi-detector CT scanner is a new scanning system with multiple distinct detector arrays.^{15,16} The CT scanner used in the present study had four detector arrays. The scanning time of the system was faster than that of conventional CT and was only 12-18 seconds for our patient.

Additionally, the scanner reduced exposure to irradiation, higher spatial resolution, and narrow slice thickness, compared with conventional CT.^{15,16}

Computed tomography findings of nonosseous tarsal coalitions include subtle articular narrowing with subchondral sclerosis.^{2,10,11,13,14} Secondary changes, such as spur and cyst formation, may also be observed.^{2,13} Kumai et al⁹ divided naviculocuneiform coalitions into three types—irregular, cystic, and combined—based on CT findings. Findings of osseous tarsal coalitions include continuity of medullary spaces of two bones.^{12,13}

Magnetic resonance imaging is useful in diagnosing tarsal coalitions.^{2,10,17} Wechsler et al¹² compared CT and MRI in the detection of tarsal coalitions. They concluded that MRI might be more helpful than CT, as CT has limitations in the depiction of fibrous coalitions. Emery et al¹⁰ also believe MRI is excellent for detecting tarsal coalitions. They, however, reported that MRI might be more difficult to read, and distinguishing low-signal cortical thickening from hypointense fibrous

tissue could be problematic. Additionally, the cost of MRI is much higher than that of CT. Computed tomography remains a more cost-effective diagnostic modality when clinical suspicion for coalition is high.¹⁰ 

REFERENCES

1. Richardson EG. Flatfoot in children and adults. In: Coughlin MJ, Mann RA, eds. *Surgery of the Foot and Ankle*. St Louis, Mo: Mosby; 1999:702-732.
2. Newman JS, Newberg AH. Congenital tarsal coalition: multimodality evaluation with emphasis on CT and MR imaging. *Radiographics*. 2000; 20:321-332.
3. Varner KE, Michelson JD. Tarsal coalition in adults. *Foot Ankle Int*. 2000; 21:669-672.
4. Stormont DM, Peterson HA. The relative incidence of tarsal coalition. *Clin Orthop*. 1983; 181:28-36.
5. Gregersen HN. Naviculocuneiform coalition. *J Bone Joint Surg Am*. 1977; 59:128-130.
6. Miki T, Oka M, Shima M, Tanaka S. Naviculo-cuneiform coalition: a case report. *J Foot Surg*. 1979; 18:81-82.
7. Miki T, Yamamuro T, Iida H, Ohta S, Oka M. Naviculo-cuneiform coalition. A report of two cases. *Clin Orthop*. 1985; 196:256-259.
8. Wiles S, Palladino SJ, Stavosky JW. Naviculocuneiform coalition. *J Am Podiatr Med Assoc*. 1988; 78:355-360.
9. Kumai T, Tanaka Y, Takakura Y, Tamai S. Isolated first naviculocuneiform joint coalition. *Foot Ankle Int*. 1996; 17:635-640.
10. Emery KH, Bisset GS III, Johnson ND, Nunan PJ. Tarsal coalition: a blinded comparison of MRI and CT. *Pediatr Radiol*. 1998; 28:612-616.
11. Marchisello PJ. The use of computerized axial tomography for the evaluation of talocalcaneal coalition. A case report. *J Bone Joint Surg Am*. 1987; 69:609-611.
12. Wechsler RJ, Karasick D, Schweitzer ME. Computed tomography of talocalcaneal coalition: imaging techniques. *Skeletal Radiol*. 1992; 21:353-358.
13. Wechsler RJ, Schweitzer ME, Deely DM, Horn BD, Pizzutillo PD. Tarsal coalition: depiction and characterization with CT and MR imaging. *Radiology*. 1994; 193:447-452.
14. Sarno RC, Carter BL, Bankoff MS, Semine MC. Computed tomography in tarsal coalition. *J Comput Assist Tomogr*. 1984; 8:1155-1160.
15. Berland LL, Smith JK. Multidetector-array CT: once again, technology creates new opportunities. *Radiology*. 1998; 209:327-329.
16. Weg N, Scheer MR, Gabor MP. Liver lesions: improved detection with dual-detector-array CT and routine 2.5-mm thin collimation. *Radiology*. 1998; 209:417-426.
17. Schoenberg NY, Lehman WB. Magnetic resonance imaging of pediatric disorders of the ankle and foot. *Magn Reson Imaging Clin N Am*. 1994; 2:109-122.